

The Mare Reproductive Loss Syndrome and the Eastern Tent Caterpillar II: *A Toxicokinetic/Clinical Evaluation and a Proposed Pathogenesis: Septic Penetrating Setae*

Thomas Tobin, MVB, MSc, PhD, MRCVS, DABT^a

J. Daniel Harkins, DVM, PhD^a

John Ford Roberts, DVM^{b,c}

Patricia W. VanMeter, BS^a

Tara A. Fuller^d

^aMaxwell H. Gluck Equine Research Center, Department of Veterinary Science, University of Kentucky, Lexington, KY 40546

^bCurrent address: Department of Pathobiology, College of Veterinary Medicine, University of Florida Gainesville, FL

^cPrevious address: Livestock Disease Diagnostic Center, University of Kentucky, Lexington, KY, 40511

^dU.S. Coast Guard Academy, New London, CT

KEY WORDS: MRLS, Eastern tent caterpillar, early fetal loss, late fetal loss, uveitis, septic penetrating setal hypothesis

ABSTRACT

Reviewing the mare reproductive loss syndrome (MRLS), it is proposed that the fundamental mechanism of this syndrome, which includes early fetal loss, late fetal loss, uveitis, pericarditis, and encephalitis, is tissue penetration by septic barbed setal fragments (septic penetrating setae) from Eastern tent caterpillars (*Malacosoma americanum*). Once ingested, these barbed setal fragments migrate through moving tissues, followed by rapid

hematogenous spread of bacteria, bacterial emboli, and/or septic fragments of setae (septic penetrating setal emboli), collectively referred to as septic materials. Pathogenic bacteria, therefore, enter the horse as hitchhikers on or in the caterpillar setal fragments, and MRLS is caused by 1) the barbed setal fragments' ability to penetrate moving tissues, including blood vessels, releasing septic materials, which rapidly distribute hematogenously; 2) the high sensitivity of the pregnant mare to bacteria from such septic materials introduced into the uterus, fetal membranes, or fetal fluids; 3) the unusually broad spectrum of bacterial pathogens carried on or in the setal

Published as Kentucky Agricultural Experiment Station Article #04-14-024 with the approval of the Dean and Director, College of Agriculture and Kentucky Agriculture Experiment Station. Publication #342 from the Equine Pharmacology, Therapeutics and Toxicology Program of the Maxwell H. Gluck Equine Research Center, University of Kentucky, Lexington, KY.

Supported by grants from the USDA Agriculture Research Service Specific Cooperative Agreement #58-6401-2-0025 for Forage-Animal Production Research, the Kentucky Department of Agriculture, the Kentucky Thoroughbred Association Foundation, the Horsemen's Benevolent and Protective Association, and Mrs. John Hay Whitney.

©Thomas Tobin, Lexington, KY, 2004

fragments; and 4) the less effective antibacterial responses in certain susceptible extracellular fluids (e.g., fetal, ocular, pericardial, and cerebrospinal fluids). The driving force for MRLS pathology, including abortions, is septic material-induced bacterial proliferation, which provides a critical amplification step, enabling approximately 1-gram caterpillars to rapidly (32 hours) cause abortions in 680-kg (1,500-lb) mares. Calculations based on the unique eye data suggest that the actual number of distributing effective septic material quanta in field cases may be small—on the order of 10/horse/day—accounting for the lack of systemic clinical signs in affected horses.

Therefore, it is proposed that MRLS starts with ingestion of Eastern tent caterpillars, followed by barbed setal fragments randomly penetrating intestinal tissues, including thin-walled venules and other blood vessels, with release of septic material that distributes hematogenously to all points in the body. Identification of abortigenic activity with the integument of the caterpillar and recent findings of large numbers of granulomatous lesions containing setal fragments in the intestines of pigs and rats directly supports the septic penetrating setal portion of the hypothesis. Analysis of the clinical syndromes and a toxicokinetic/statistical analysis of MRLS suggest that setally-mediated introduction of septic material into blood vessels and other tissues may be key to understanding the very unusual toxicokinetics and pathogenesis of the unique group of syndromes that constitute MRLS. Like MRLS itself, this hypothesis is unique. The septic penetrating setal emboli portion is without precedent, is based on the unique clinical characteristics of MRLS, and appears well supported by ongoing experimental approaches.

BACKGROUND

Early in July 2002, a review of the literature provided information regarding the ability of barbed caterpillar setae to penetrate tissues, particularly the human eye.¹⁻³ It was easy to visualize setal fragments from orally ingested Eastern tent caterpillars

(*Malacosoma americanum*) similarly penetrating the intestinal wall, entering small blood vessels, and facilitating entry of bacteria into the blood stream. This simple concept, however, left unanswered how rapid bacterial penetration through distant maternal/fetal membranes might occur or how the unusual pericarditis lesions or the virtually unique unilateral eye lesions might occur.^{4,5}

Using a pharmacologic approach, the consequences of the penetrating setal fragments or related materials entering blood vessels redistributed hematogenously were considered. If the distribution of these materials follows cardiac output similar to that of an orally absorbed drug, the unusual bacteriologic and other characteristics of the various discrete clinical syndromes that constitute MRLS and the lack of clinical signs in affected mares, despite the very rapid onset of the syndrome, become more understandable, as will now be detailed in this report.

The hypothesis was communicated on a confidential basis to selected colleagues; most were skeptical. The hypothesis was first presented formally in its septic penetrating setal emboli-format at the 2002 Bain-Fallon Lectures in July 2002 in Australia and shortly thereafter at the First Workshop on Mare Reproductive Loss Syndrome in Lexington, KY.⁶ Later, the hypothesis was registered with the Copyright Office of the Library of Congress.⁷ More recently, observations demonstrating the presence of large numbers of setal fragments in the intestinal walls of pigs,⁸ rats,⁹ and a horse¹⁰ offer strong support for the proposed first step of this hypothesis. Based on this experimental evidence consistent with the first step of the hypothesis and a recent unique toxicokinetic/statistical analysis of MRLS also consistent with this proposed pathogenesis,¹¹ a full current draft of this hypothesis—the “septic penetrating setal” hypothesis of MRLS—is presented here.

HYPOTHESIS

The possibility must be considered that simple tissue or intestinal penetration by barbed

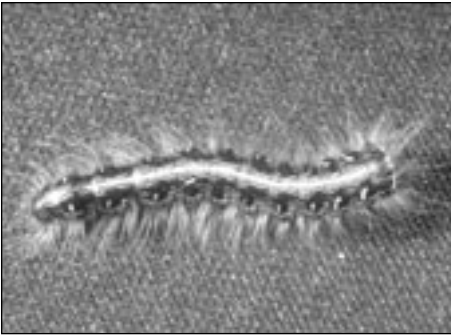


Figure 1. Mature sixth-instar Eastern tent caterpillar. The head is to the right, showing distribution of setae. A mature female Eastern tent caterpillar measures up to 6 cm long and weighs up to 1.5 g; the mature male is somewhat smaller. Photo courtesy of Dr. Richard Bessin, University of Kentucky.




Figure 2. Fine structure of selected Kentucky Eastern tent caterpillar setae, showing barbed structures. Panel **A** shows a portion of the barrel of a seta approximately 20 μm in diameter. Note that the barbed structures point towards the tip. Panel **B** shows the tip of the same setal fragment, again with the barbs pointing toward the tip. The diameter of the setal fragment and its tip are approximately the same as that of an equine pulmonary capillary. Photos courtesy of Henry H. Southgate, University of Kentucky.

setal fragments of Eastern tent caterpillars, with associated bacterial “hitchhikers” (septic penetrating setae) followed by hematogenous distribution of septic materials is the fundamental pathophysiological mechanism of each of the five recognized MRLS syndromes: early fetal loss, late fetal loss, unilateral uveitis, pericarditis, and the more recently reported *Actinobacillus* encephalitis.

The hypothesis is described in detail, and it has been named the septic penetrating setal hypothesis of MRLS. The hypothesis is specifically written to include initial tissue penetration by septic setal fragments from Eastern tent caterpillars; penetration of moving tissues; and hematogenous distribution of bacteria, bacterial emboli, and septic penetrating setal emboli (collectively referred to as septic materials), ultimately yielding the differing clinical syndromes comprising MRLS. The pivotal assumption in this hypothesis is that in seeking to understand MRLS, the combined effects of four key steps were previously underestimated.

PROPOSED MECHANISM

Step 1. Tissue Penetration

Penetration and migration of barbed caterpillar setal fragments in moving tissues is

proposed to be the first step of the syndrome. Exposure to Eastern tent caterpillars’ barbed setal fragments results in penetration of the oral or intestinal mucosa or other tissues by setal fragments and the nonspecific introduction of local commensal bacteria (hitchhikers), which in the oral cavity may be *Actinobacillus* and nonhemolytic streptococci. When experimental exposure occurs via the intestinal or other routes, the bacteria introduced may be *Serratia* spp or other commensal, intestinal or other bacterial hitchhikers (Figures 1–4).

Step 2. Blood Vessel Penetration and Distribution

The migration of setal fragments takes place by virtue of their barbed structures in moving tissues. A proportion (most likely a small proportion) of these septic fragments penetrate blood vessels (Figure 5) and release septic material, which rapidly distributes hematogenously.

Step 3. Distant Tissue Penetration

The rapid hematogenous relocation of septic material to points distant from the point of entry, the retained ability of the septic material to penetrate moving tissues, and the apparent high sensitivity of the fetoplacental unit to these materials (especially in com-

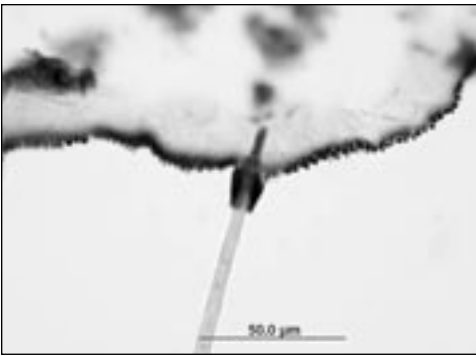


Figure 3. Light micrograph of the base of Eastern tent caterpillars setae at the site of insertion into the caterpillar integument. The estimated width of the seta is 5 μm and it appears that the setal structure is hollow. Photo courtesy of Dr. John Roberts, University of Kentucky. (hematoxylin–eosin, magnification $\times 400$).

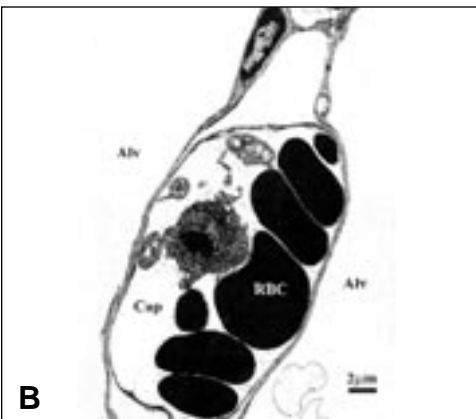



Figure 4. Eastern tent caterpillar segment showing a terminal setal fragment 83 μm in length and 2 to 3 μm in width (**A**). Caterpillar integument is present in the upper left corner of the photo. Photo courtesy of Dr. John Roberts, University of Kentucky (trichrome stain, magnification $\times 1000$). Electron micrograph of an equine pulmonary capillary with erythrocytes and leukocytes and an apparent setal fragment (**B**). The internal diameter approaches 10 μm . Photo courtesy of Dr. E. Birks, University of Pennsylvania.

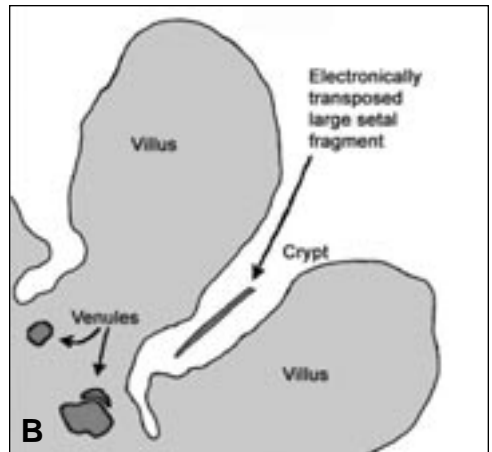
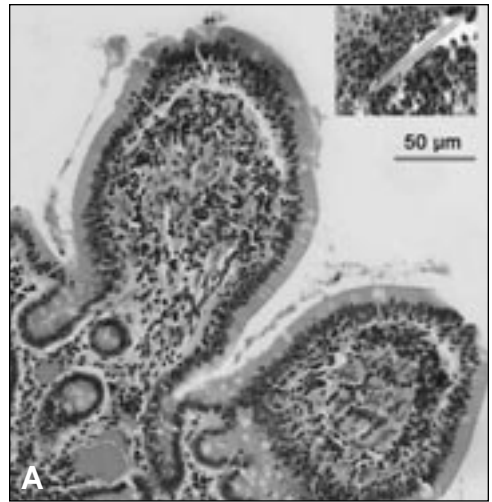


Figure 5. Spatial relationships with reference to intestinal setal penetration. A section of mucosa from the small intestine of a horse, with a cross section of intestinal villi, crypts, and numerous thin-walled blood vessels filled with erythrocytes, and one vessel about 50 μm in diameter close to the surface of the crypt (**A**). The inset shows a large setal fragment found embedded in rat intestine after oral administration of Eastern tent caterpillars, at the same magnification. A setal fragment randomly entering the crypt, with appropriate barb orientation, will move deeper into the crypt driven by intestinal movements and potentially penetrate the intestinal wall. A fraction of such penetrating setae will randomly enter blood vessels (**B**). Some of these blood vessels will be sufficiently large to accommodate the setal fragment. Note the relatively large size and thin walls of the large blood vessel outlined and the relatively short distance between the intestinal exterior at base of the crypt and the blood vessel itself. Photos courtesy of Dr. Manu Sebastian and Mr. Charlie Hughes, University of Kentucky.

Table 1. Bacteriologic Findings from Fetuses Evaluated in Mare Reproductive Loss Syndrome Abortions in 2001

Isolate	Number of fetuses (%)
Non- β hemolytic streptococci	223 (51.5)
Actinobacilli	74 (17.1)
Actinobacilli and non- β hemolytic streptococci	8 (1.8)
<i>Escherichia coli</i>	7 (1.6)
<i>Pantoea agglomerans</i>	4 (0.9)
<i>Serratia marcescens</i>	2 (0.5)
<i>Aeromonas</i> spp.	4 (0.9)
<i>Enterobacter</i> spp.	0
<i>Acinetobacter</i> spp.	4 (0.9)
β -hemolytic streptococci	2 (0.5)
<i>Staphylococcus</i> spp.	1 (0.2)
Other coliforms	4 (0.9)
Other bacteria	4 (0.9)
No significant bacteria	70 (16.6)
Overgrown by saprophytes	26 (6.2)
TOTALS	433 (100)

Adapted from and reproduced with permission from Donahue et al, 2003.⁴⁸

parison with the sensitivity of nonpregnant horse, mice, rats, and possibly other animals) is the next step in the syndrome.

Step 4. Variable Defense Resources

The final step is the poor antibacterial responses in clinically affected tissues. Rapid bacterial growth follows bacterial contamination of fetal and other extracellular fluids, which results in fetal loss.¹² The eye is immunologically privileged, and its extracellular fluids are less well protected than many tissues.¹³ The brain and cerebrospinal fluid also have immunologic deficits, as highlighted by equine protozoal myeloencephalitis. Alone among the clinically affected tissues, a clear immunologic deficit cannot be associated with the pericarditis lesions, although the pericardial fluid itself may, as an extracellular fluid, be less well protected. Additionally, it is likely that the pericardial lesions relate in part to the motility and central location of the heart in the circulatory system and its resultant high level of exposure to blood-borne septic material, especially septic penetrating setal emboli.

In most tissues, small numbers of "lodged" septic materials are readily handled by the specific and nonspecific

immune systems and cause no clinically significant or apparent long-term damage. However, the lack of effective antibacterial systems in fetal fluids appears to leave the fetus largely unprotected once bacterial contamination of fetal fluids occurs, leading rapidly to the early and late fetal loss manifestations of MRLS (Table 1). The nonspecific nature of the proposed bacterial transport system is consistent with the wide range of bacterial pathogens recovered from MRLS fetuses (Table 1).

Like MRLS itself, this hypothesis is unique, and the portion of this hypothesis regarding septic penetrating setal emboli is apparently without precedent in biology or medicine. In its support, this hypothesis fits well the unique toxicokinetics of MRLS set forth in an earlier communication,¹¹ and it also fits the unique grouping of clinical syndromes that constitutes MRLS. Additionally, the hypothesis is well supported by recently acquired evidence concerning multiple setal fragment penetrations in the intestines of various animal species that were fed Eastern tent caterpillars (Figure 6), the unusual speed of onset of the abortions, calculations concerning the likely numbers of circulating septic material quanta, the difficulty in culturing bacterial pathogens from the blood of

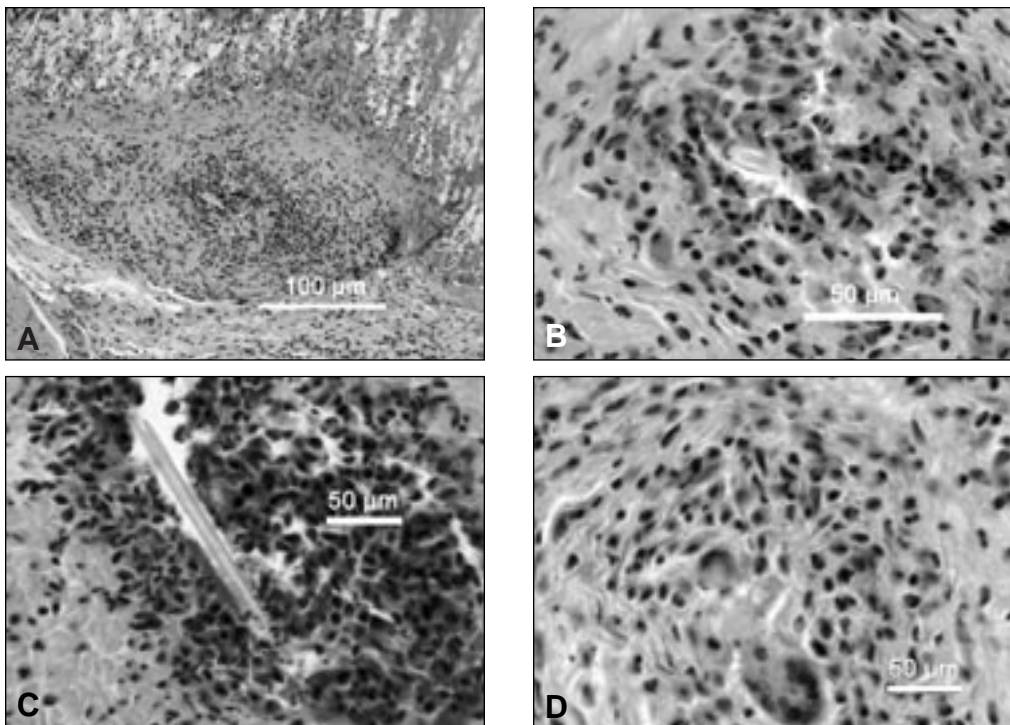


Figure 6. Setal fragments lodged in gastric submucosal tissue from a rat given Eastern tent caterpillars by gavage, showing extensive granulomatous reaction (**A**) and a close-up of the setal fragment surrounded by histiocytes (**B**). Another setal fragment, apparently hollow, surrounded by inflammatory cells and granulomatous reaction (**C**), and a small setal fragment surrounded by inflammatory cells, including a multinucleated giant cell (**D**) (hematoxylin-eosin, magnification ? 400). Photomicrographs courtesy of Dr. Terrence Fitzgerald, State University of New York, Cortland, NY and Dr. Manu Sebastian, University of Kentucky.

affected horses, and the very unusual lack of systemic clinical signs in affected horses.

HEMATOGENOUS SPREAD OF SEPTIC MATERIAL AND MRLS SYNDROMES

From clinical cases and experimental work, it appears that the initiating event in each of the MRLS-associated syndromes is local bacterial infection of hematogenous origin, with the bacteria initially entering the blood stream at the site of exposure to the caterpillar. The cardiac and encephalitic syndromes cannot be other than hematogenous in origin. The unilateral ophthalmitis cases are also consistent with and best explained by a hematogenous source. In particular, a number of these cases apparently started with hemorrhage deep in the eye, and the difficulty in treating these cases is consistent with a septic hematogenous insult originat-

ing deep in the eye. Additionally, none of the affected eyes was fluorescein-positive, suggesting that no significant corneal damage or penetration had occurred. Beyond this, recent experimental work has shown that topical exposure to caterpillars failed to reproduce characteristic MRLS-associated eye lesions (Personal communication, B. Bernard, 2002), further suggesting a blood-borne ophthalmitis.

PRELIMINARY EXPERIMENTAL EVIDENCE

Analysis of experimental work with late fetal loss in 2002¹⁴ suggested that bacterial proliferation was its driving force and that the source of the fetal bacterial pathogens was hematogenous and not ascending (i.e., via the cervix) in origin. This observation was key in developing this hypothesis.

Previously, a toxin was considered to be responsible for death of the fetus, and bacteria cultured from the fetus were thought to be secondary invaders.

This hypothesis was next supported by experiments by Bernard and coworkers (B. Bernard, unpublished data, 2002), in which early fetal loss was reproduced in mares given Eastern tent caterpillar integuments by stomach tube;¹⁵ Similar results were reported by Webb et al.¹⁶ Studies in pregnant mice also suggest that intraperitoneal administration of a homogenate of fresh setae may lead to reabsorption, as occurred in fetuses in three of six treated mice,¹⁷ although results of this study were not repeatable in one attempt with frozen Eastern tent caterpillar setae.

CLINICAL CONSEQUENCES OF SETAL/BARBED FOREIGN BODY MIGRATION

Background

This section provides a review of the literature on clinical, microbiologic, and pathologic changes associated with tissue penetration by barbed foreign bodies. The biomedical literature on barbed structures includes those associated with several animal and plant species. This review leads to some general conclusions concerning the pathophysiology of conditions caused by or associated with barbed structures.

Caterpillar Setae

Caterpillar setae are often barbed and have been known to penetrate the human eye. Since the 19th century, a condition known as ophthalmia nodosa, in which a granulomatous nodule is formed on the conjunctiva and iris in response to caterpillar setae, has been reported.¹⁸ Numerous other reports of endophthalmitis, conjunctivitis, and uveitis caused by direct ocular exposure to caterpillars or following dissemination of setae by wind formed an important starting point for the setal hypothesis of MRLS.^{2-4,19,20}

Although setal penetration of tissues other than the eye is rarely described in the

medical literature, one retrospective study of 10 patients presented to a pediatric emergency department following ingestion of caterpillars detailed the extent of setal lesions associated with tissues other than the eye.²¹ In these cases, caterpillar setae were removed from the tongue (n = 7), lips (n = 5), oropharynx (n = 5), cheeks (n = 4), buccal mucosa (n = 4), abdomen and legs (n = 2), esophagus (n = 1), and neck (n = 1). The lesions had no long-term effects, and none of the patients experienced anaphylactic reactions.

Caterpillar setae have caused numerous cases of dermatitis through direct and airborne contact with human skin. Because vacationers annually developed an erythematous dermatitis including vesicular eruptions while camping in the dunes region of Ameland, Netherlands, a study was performed to determine whether caterpillars of brown tail moths (*Euproctis chryorrhoea* Linn.) were the cause. Dermatitis occurred in over 70% of the volunteers that had setae from the caterpillars taped to their back.²²

Similarly, 165 soldiers and civilians from the United States military community in Heidelberg, Germany required treatment for acute dermatitis during one week in the summer of 1995, compared with the usual average three per day. Those affected complained of a painful, itching rash distributed widely over the body. Urticarial hairs from the oak processionary caterpillars, which live in communal webs on oak trees, were identified as the cause. Outbreaks of dermatitis associated with the oak processionary caterpillar were reported throughout that region and also in Livorno, Italy.²³

Other species of caterpillars have been reported to injure large numbers of military personnel. Urticaria from dead caterpillars and old cocoons of *Thaumetopoea wilkinsoni* Tams caused a rash and severe irritation to 600 soldiers camped in a pine grove in Italy.²⁴

In Sydney, Australia, several employees and clients at a community center experienced skin reactions and irritations for more than 4 months.²⁵ Outside the center, a large

colony of caterpillars was living in a eucalyptus tree about 10 meters from the intake vent of the air-conditioning system.

Caterpillar-like hairs were identified in dust samples from inside the center. Based on reports of successful use of sticky tape to sample affected areas for jellyfish stings, caterpillar hairs were removed from two of the three people thus tested. Following removal of the caterpillar nest and thorough cleaning of the center, no further dermatitis cases were reported.

Other Barbed Structures

Further review of the literature revealed reports of pathological changes associated with tissue penetration by barbed structures from tarantulas,²⁶ porcupine quills,²⁷ stingrays,^{28,29} Portuguese man o' war,³⁰ catfish,³¹ cacti, Phoenix date palm,^{32,33} pappus plant of South Africa,³⁴ and grass awns.³⁵ These clinical reports indicate that barbs are a widespread means of protection and aggression in nature. Barbed structures may enter the body by any route, including the intestine. They can penetrate anywhere, including into the brain through the foramen magnum. Once lodged, these structures migrate, and the rate of migration depends only on the rate of movement of the host tissue. Tissue movements serve to "ratchet" the barbed structure along in random directions through any moving tissue. Most of the barbed structures noted above are relatively large and take days, weeks, or even months to migrate through soft tissues to the point of clinical presentation. In sharp contrast, however, exposure to setal fragments of Eastern tent caterpillars can cause abortions in pregnant mares within 30 hours of their intubation.

To maximize the effectiveness of barbed structures as a defensive mechanism, the numbers of barbed structures deployed should be large. Additionally, a means of accelerating their distribution through the target body would be helpful. The barbed setal fragments of Eastern tent caterpillars may have effectively solved these problems. The setae are present in large numbers, and

fragmentation presumably further increases that number. The fragments (or some portion of the fragments), however, are sufficiently small that at least a fraction of them distribute hematogenously (and therefore rapidly) as septic material, septic penetrating setal emboli, or equivalent materials, giving rise to the five distinct syndromes that constitute MRLS, which can have an extremely rapid onset both in the laboratory and in the field (at least for late fetal loss).

BACTERIA/BACTERIAL EMBOLI/ SEPTIC PENETRATING SETAL EMBOLI

Septic Penetration

The second step in this hypothesis is that the setal fragments penetrate blood vessels, especially thin-walled veins, and release septic material, a proportion of which redistribute rapidly through the blood to new and more distant locations in the body. All such septic material movements are passive, secondary to tissue movement or blood flow (cardiac output), and all events are statistically determined. These events presumably occur at some level in all species exposed to Eastern tent caterpillars, apparently with only occasional adverse health consequences, as indicated by the relatively low incidence of adverse events in nonpregnant horses and other species experimentally challenged.

Starting Numbers of Septic Penetrating Fragments

For this mechanism of MRLS to be effective, the starting number of setal fragments should optimally be large, since all penetration and distribution events are statistically determined. This requirement is consistent with recent estimates that mares aborting in 2001 were exposed to the equivalent of 5 to 30 grams of Eastern tent caterpillars per day.¹¹ Beyond this, recent reports indicate that the intestinal tracts of pigs necropsied following exposure to orally administered Eastern tent caterpillars contained large numbers (estimated 10^5 or 10^6 per pig) of small setal fragments encased in microgranulomatous masses.⁹

Septic Material Distribution

The hypothesis is specifically written to cover three distinct possibilities. It assumes the primary entry of the pathogenic bacteria is associated with the penetrating setal fragments. The second step, the hematogenous spread of septic material, may involve distribution of bacteria, bacterial emboli, or septic penetrating setal emboli. Although some clinical characteristics of MRLS may best be explained by the septic penetrating setal emboli hypothesis, the possibilities that the septic material are simply bacteria or bacterial emboli redistributed by blood flow are specifically included in the hypothesis. In any event, distribution and entry of a broad spectrum of septic material (Table 1) into the fetal membranes occur, and the pregnant mare is apparently highly susceptible to both early and late fetal loss from hematogenous redistribution and subsequent exposure to the septic material.

Distributing Septic Penetrating Setal Emboli and the Lung

The septic penetrating setal emboli portion of this hypothesis requires that hematogenously spread setal fragments either pass through or bypass the lung capillary beds to enter the systemic circulation. Whereas the Eastern tent caterpillar setal fragments observed in pig and rat intestinal tissues are small barbed cylinders about 15 to 25 μm in diameter and 100 μm in length, the question arises as to how such fragments could pass through the lung capillary beds. Three mechanisms are suggested that may allow movement of septic penetrating setal emboli past or through the lung capillary beds and into the systemic circulation.

An obvious mechanism is movement of the material through the lungs in the same way they enter into and move through the intestine. Specifically, they may be driven or “ratcheted” along through lung tissues by respiratory movements, which will eventually allow passage of some portion of septic penetrating setal emboli to enter the lung.

Septic penetrating setal emboli may also

bypass lung capillary beds through well-characterized anatomical and pathological shunts. Studies by Gillespie and Tyler³⁶ and Littlejohn and others³⁷ estimate the venous admixture (anatomic shunts) in the pulmonary circulation to be about 5% in normal horses and 9% in horses afflicted with emphysema, which are pathologic shunts.³⁷ In another study of respiratory function, the venous admixture (shunted fraction) was determined to be about 9% in normal horses and 26% in horses with chronic obstructive pulmonary disease. Anatomic and pathologic shunts therefore provide a mechanism for septic penetrating setal emboli to rapidly bypass lung capillary beds and enter the systemic circulation.

Finally, it is also possible that some septic material/septic penetrating setal emboli fragments are small enough to pass relatively unhindered through capillary beds, as suggested by the apparently very small diameter of some setal fragments compared with the diameter of equine lung capillaries (Figures 2–4).

GENERATING BACTEREMIA, BACTERIAL EMBOLI, OR SEPTIC PENETRATING SETAL EMBOLI: THE PROTECTIVE FUNCTION OF SETAE FOR THE CATERPILLAR

Clinical Evidence for Tissue Penetration by Caterpillar Setae and Hairs

Historically, the ability of “hairy” caterpillars to cause oral lesions in horses is specifically noted in an unreferenced citation³⁸ that states “*Elongated shallow erosions (2 × 0.5 cm) can occur in profusion in the mouths of a large proportion of a band of horses grazing pasture infested with hairy caterpillars or pastures containing grass with bristly seedheads*” (emphasis added). Beyond this, the fundamental assumption that small barbed setal fragments can penetrate moving tissues will come as no surprise to members of the hairdressing and dog grooming professions, where the ability of short hair fragments to penetrate human skin, usually in

the spaces between the fingers or toes (note the obvious parallel structural relationships presented in Figure 5) and cause cutaneous conditions known as trichogranulomas and pilonidal sinus is a widely recognized hazard in these professions (Personal communication, Nancy DeJarnette, 2002).^{39,40}

The Role of Intestinal Absorption

For the purposes of this hypothesis, the equine intestinal tract, with its crypts and villi and ongoing peristaltic movements, may be viewed as an ideal organ to “trap” barbed setal fragments and propel setal fragments into and through its tissues. With its network of apparently thin-walled absorptive blood vessels, it also is a body system likely to yield bacteria, bacterial emboli, or septic penetrating setal emboli following exposure to Eastern tent caterpillars (Figure 5). The findings that *Serratia* are associated with both Eastern tent caterpillars and MRLS and that *Actinobacillus* and non-hemolytic streptococci may be oral commensals also focus attention on the introduction of Eastern tent caterpillars’ surface bacteria and/or oral commensal bacterial into the blood stream as an integral part of the pathogenesis of MRLS. In this regard, the apparent efficacy of muzzling mares during the 2002 caterpillar season as well as the recent work of Webb et al¹⁶ demonstrating the efficacy of oral exposure seems to suggest considerable (perhaps critical) importance for the oral route of exposure.⁶

THE STRUCTURE AND FUNCTION OF CATERPILLAR SETAE

To the authors’ knowledge, little attention has been given to the fine structure and function of simple barbed setae in Eastern tent and similar caterpillars. These structures have presumably evolved in a manner calculated to maximize the digestive discomfort or other adverse responses associated with their ingestion, it not being in the interests of Eastern tent caterpillars to be perceived as palatable. Although the setae of Eastern tent caterpillars are readily distinguishable from poisonous setae, they pre-

sumably also serve a protective function for the caterpillar.

Therefore, the possibility should be considered that mechanical penetration and facilitation of bacterial entry is an aversive/defensive mechanism associated with barbed setae of certain caterpillars. In this regard, these setae may well have evolved so that their setal protective mechanism is to facilitate the entry of bacterial pathogens into their predators. The introduced bacteria then proliferate and serve a destructive function broadly similar to the enzymatic toxins of the poisonous *Lonomia* caterpillar species.⁴¹ This is, presumably, a cost-effective defensive strategy for the caterpillars, the bacterial pathogens substituting for the poisons, toxins, or venoms of other species, with a significant saving of resources for the caterpillar.

This setal defense mechanism may be most effective when the dose delivered to the affected animal is relatively high, as it would be for a bird, for instance, as opposed to the much smaller caterpillar:horse ratio operative in MRLS. Furthermore, this is presumably an ancient caterpillar defense mechanism; as such it would also not be surprising if setal fragments used specific configurations (e.g., their apparently hollow structure) or other factors or materials to facilitate bacterial transportation or tissue penetration, similar to the saliva of blood-sucking parasites that contains specific inhibitors of blood coagulation. In fact, loss of such associated facilitating factors may be one limiting factor for Eastern tent caterpillar abortigenic activity. Finally, the familiar clustering behavior of Eastern tent caterpillars may represent a classic cooperative defensive mechanism, with the clustered group minimizing their individual risk/exposure, while maximizing their group setal defense (Figure 7).

There may also be dimensional considerations involved in the overall process of MRLS. The large size of the horse presumably means there are similarly large numbers of intestinal venules with dimensions

appropriate for capture of penetrating setal fragments and initiation of the hematogenous redistribution events associated with the septic material (Figure 5). In this regard, it is of interest that attempts to reproduce MRLS in pregnant rats and mice have not been particularly successful, whereas experiments in swine have apparently been more productive.

MRLS 2001, as we know it, may simply be a recently identified peracute manifestation of a long established Eastern tent caterpillar defensive mechanism. It was on this basis that, as soon as Eastern tent caterpillars became available in 2002, the authors' investigations were immediately focused on their setae.¹⁷ For reasons not readily apparent, the pregnant mare is exceptionally sensitive to this defense mechanism. Nonpregnant horses, however, show a low level of clinical response, as indicated by the very low incidence of ocular and cardiac syndromes in nonpregnant horses from data collected in 2001 and 2002.

UNUSUAL SUSCEPTIBILITY OF THE PREGNANT MARE TO SEPTIC MATERIAL

Role of Myometrial and General Locomotor Activity

Hematogenously distributed bacteria, bacterial emboli, or septic penetrating setal emboli lodged in a uterine blood vessel of a pregnant mare will again migrate through these tissues when the mare moves.

Myometrial movement, either due to the musculature of the myometrium itself or the physical activity of both the mare and fetus, will drive migration of those materials, and eventually, the septic material will penetrate the fetoplacental unit.

Role of Fetal Membrane Penetration

Well-established clinical experience suggests that very modest bacterial contamination of amniotic fluid can initiate rapid bacterial overgrowth, followed by death and expulsion of the fetus within a day or days (Personal communication, Dr. Jim Bowen,

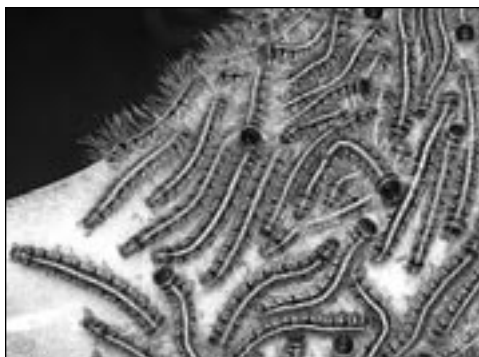

Figure 7. A cluster of mature Eastern tent caterpillars on their tent, showing group clustering behavior and fine setal structure. Photo courtesy of Dr. Terrence Fitzgerald, State University of New York at Cortland, NY.

2002). Based on this experience, penetration of the fetal membranes by a modest quantity of septic material would presumably be sufficient to produce early or late fetal loss. Review of 2002 Eastern tent caterpillars/late fetal loss experimental data¹⁴ suggested that bacterial proliferation was a primary or driving event in late fetal loss, apparently occurring before there were any signs of fetal distress and death. As mentioned earlier, identification of the key driving role of bacterial proliferation in late fetal loss syndrome was a critical factor in development of this hypothesis for MRLS.

The Role of Fetal Size and Movement

A striking characteristic of experimental MRLS is the speed with which experimental late fetal loss can occur, with recent work indicating that the first losses occurred within 32 hours.¹¹ It is suggested that the late fetus presents a large "capture area" for randomly distributing septic material. Therefore, a late fetus is statistically more likely to be "hit" by the septic material within a given period than would an early fetus, which would be considerably smaller. Additionally, uterine movements are likely to be more pronounced in a mare carrying a late fetus, driving the tissue migration of septic material that is lodged in uterine tissue, and ensuring their rapid penetration through a fetal membrane. Together, these

steps may explain the apparent more rapid onset for late fetal loss than for early fetal loss, particularly for experimentally induced late fetal loss with high doses of caterpillar setae. In studies recently reported by Webb et al¹⁶ that primarily involved early fetal loss, the time course of the abortions was slower than that observed for late fetal loss, consistent with the proposed model of the pathogenesis of MRLS.

Role of Delayed Fetal Membrane Penetration

The hypothesis also readily explains cases of early or late fetal loss occurring some time after exposure to caterpillars has concluded. Inopportune location of septic material, especially septic penetrating setal emboli, in an area of the myometrium with lower motility will delay the entry of septic material into the fetal membranes, yielding early or late fetal loss some time after exposure to Eastern tent caterpillars has ceased.

The Critical Lack of Positive Blood Cultures and Systemic Clinical Signs

The septic penetrating setal emboli (and to some extent the bacterial emboli) models are consistent with the lack of positive blood cultures and virtual absence of systemic clinical signs of bacteremia in mares experiencing early or late fetal losses. The explanation for this is that blood-borne bacterial contamination is carried in small numbers of discrete quantal packets on (or in) individual setal fragments or bacterial emboli and not diffusely throughout the bloodstream. The fact that it has been difficult to identify positive blood cultures in mares affected by MRLS may be more consistent with the septic penetrating setal emboli portions of this hypothesis than with the simple bacteria or bacterial emboli portions.

Similarly, the virtual absence of clinical symptoms in mares undergoing late fetal loss within hours of being dosed with Eastern tent caterpillars by intubation speaks strongly against simple setally induced "loss of intestinal integrity" and resultant bacteremia inducing MRLS.

Studies conducted by the authors indicate that IV infusion of small amounts of lipopolysaccharide endotoxin is more than sufficient to rapidly induce significant and easily discernible systemic clinical signs and clinical chemistry changes in horses.^{42,43} Given the sensitivity of horses to small amounts of lipopolysaccharide, it is difficult to imagine a sequence of events in which a loss of intestinal integrity and resultant bacteremia sufficient to induce abortions within 32 hours would occur without detectable clinical or clinical chemistry changes in the mare(s).

The Need for an "Amplification Factor"

One of the most striking aspects of MRLS is the apparent enormous potency of the caterpillar "factor" on a body weight basis. Caterpillars have very little mass (approximately 1–1.5 g) compared with that of horses. The authors' experience as toxicologists suggests the improbability of small numbers of caterpillars producing sufficient quantities of any orally absorbed toxin to rapidly cause abortions in 680-kg mares, let alone a toxin with essentially no other reported signs of toxicity. This question has led to suggestions of a required biological amplification step (viral contaminants, fungal overgrowth on frass, etc.) to provide the requisite amplification factor.

The bacterial proliferation step described herein provides the requisite biological amplification factor that presumably enables a single septic penetration of a fetal membrane to produce early or late fetal loss in 680-kg mare.

THE UVEITIS, PERICARDITIS AND ENCEPHALITIS CASES

The hypothesis requires that all horses in central Kentucky (not just pregnant mares) exposed to Eastern tent caterpillars suffer essentially equivalent episodes of septic material dispersion. It is proposed that the concomitant uveitis, pericarditis, and encephalitis cases, which occurred across central Kentucky in horses of both sexes and all ages, are clear evidence of this process at

work in a systematic fashion, albeit at a very low level (1/1,000 horses or so), in the entire “at risk” population of horses during the period when MRLS occurred in central Kentucky in 2001.

The Unilateral Uveitis Cases

It is well established that the cases of uveitis are of hematogenous origin. It is proposed that the primary event in a uveitis case is hematogenous delivery of a quantum of septic material to the eye. The very low incidence of uveitis observed is presumably related to the relatively small target size (capture area) and the equivalently small fraction of cardiac output supplying an individual eye.

A significant argument in favor of the septic penetrating setal emboli portion of this hypothesis is the fact that all reported cases of uveitis were unilateral. This observation fits a quantal and entirely random hematogenous distribution of very small numbers of septic penetrating setal emboli, as compared with hematogenous distribution of bacterial emboli and especially bacteria. Their delivery is less likely to be so clearly quantal in nature.

With reference to Step 4 above, the eye is also an immunologically privileged area. As such, it may be particularly susceptible to damage by penetrating septic material. Our ability to observe eye pathology associated with MRLS is also most likely due to the ease of observing events occurring in the eye and the highly significant consequences of eye damage compared with limited local damage in other areas of the body and the possible therapeutic and immunologic difficulty of controlling a septic focus that has entered deep in the eye.

Uveitis Cases and the Number of Circulating Septic Material Quanta

The very small number of unique unilateral uveitis cases observed may allow us to define a lower limit for the total number of “effective septic material quanta” distributing in the blood of the average horse in central Kentucky during MRLS 2001.

Assuming there are approximately 30

cases of unilateral uveitis in about 30,000 exposed horses, the overall minimum “effective septic material quantal hit rate” (considering both eyes per horse) is approximately 30 cases per 60,000 eyes or 1 case per 2,000 eyes. Based on these figures, the probability of any single horse in central Kentucky showing two overlapping cases of unilateral uveitis is not less than about 1 in 4,000,000.

Assuming that each eye weighs approximately 0.11 kg (0.25 lb), the overall average 2001 probability of a hit would be 1 per 227 kg (500 lb) of equine tissue, or about two total septic material quanta per horse for the entire 2001 MRLS period. A mature fetoplacental unit, which weighs about 63.5 kg (140 lb), will have (based on its mass) approximately a 25% probability of a single effective “hit”. Similarly, the early fetoplacental unit, which weighs approximately 11.4 kg (25 lb), should expect an overall hit rate in the area of about 2% to 3%.

Although these figures bracket the overall early and late fetal loss rate of about 17%, they do not appear to reflect the apparent much greater rate of early fetal loss during MRLS 2001. However, it should also be noted that these estimated total average numbers of distributing effective septic material quanta are extremely small (considerably less than one effective septic material quanta per horse per day).

These estimates are, of course, averages calculated over the entire population of horses at risk in the 2001 season in central Kentucky. Some individual farms, individual groups of horses, and individual horses will have had much greater rates of exposure; however, the reality of the situation determined from the eye data and the calculations above is that the actual numbers of effective septic material quanta that reach the systemic circulation are apparently quite small, even during 2001, the most intense epidemic of MRLS on record.

The Pericarditis Cases

The pericarditis cases presumably represent septic material that enters the coronary blood

supply, lodge in blood vessels, and migrate through the moving/contracting cardiac vessels and tissue. Of all tissues in the body, the contracting heart is one through which one might expect bacteria, bacterial emboli, or septic penetrating setal emboli to migrate fastest. Additionally, for every one of these entities that migrate out and appear at the epicardial surface, at least one migrates in the opposite (or other) directions. Presumably, a larger number of subclinical cases of epicarditis associated with the MRLS episodes occurred and resolved spontaneously.

A problem with this portion of the hypothesis is that, to date, pathologists have reported no evidence of setal tracks in cardiac tissues. A careful search should be made for signs of subclinical pericarditis associated with intestinal exposure to Eastern tent caterpillars. The central role of the heart in the circulatory system and its ongoing contractile activity may suggest a considerable probability of transient positive histologic and bacteriologic culture findings in pericardial fluid associated with Eastern tent caterpillars exposure. Conversely, analysis of recent data from the study in pigs suggests that the penetrating setal fragments are relatively small, and the eye data suggests that the actual numbers distributing may be very few, with numbers in the order of 10–100 per horse, representing relatively large numbers of distributing septic material quanta. Given this circumstance, it may be challenging to detect setal tracks in cardiac tissue. In this regard, it is worth noting that the microgranulomas associated with lodged setae in the intestinal tract of pigs and rats are themselves very small, and not grossly observable.⁹

Bacteria cultured from the pericarditis cases are those associated with MRLS, but no bacteria were cultured from some pericarditis cases. This may suggest loss of septic contaminants during passage of the septic material through cardiac musculature. The pericarditis cases may also be most consistent with and best explained by the septic penetrating setal emboli portion of this hypothesis.

The Encephalitis Cases

Since MRLS was first described, three specific cases of *Actinobacillus* encephalitis have been recognized as having occurred during the same period. Similar to the cases of pericarditis, these cases are unquestionably hematogenous in origin and occurred in about the same time period as MRLS.¹⁴

INTELLECTUAL ECONOMY OF THE HYPOTHESIS

Subsequent to investigation of the possibility of cyanide toxicity as the cause of MRLS, focus was placed on Eastern tent caterpillars setae because of their well established overall role in general caterpillar defense mechanisms. This setal hypothesis is a modification and simplification of the hypothesis that drove the first setal experiment in mice, which assumed that the setae were introducing a protein or other toxin or factor that was the primary pathogen.¹⁷ Further reflection on the matter, along with identification of bacterial proliferation as the driving force in MRLS, suggested that a setal toxin is not necessarily required, as set forth above. Additionally, the speed of onset of late fetal loss in laboratory experiments also does not suggest a classic catalytic toxic mechanism. For example, the enzymatic fibrinolysin toxin of the *Lonomia* caterpillar in Brazil takes up to one week to kill a human, consistent with an ongoing low-level catalytic/toxin activity.⁴⁴ In contrast, experimental late fetal loss abortions can occur within 32 hours of exposure to Eastern tent caterpillars.

The hypothesis does not require the presence of any additional toxins in the caterpillars, such as cyanide, cyanide precursors,^{45–47} viruses, microsporidia, unusual weather patterns, plant toxins, frass, or fungal overgrowth on frass; it simply requires Eastern tent caterpillars.

A clear characteristic of MRLS has been that no evidence of toxins, viruses, mycotoxins, other than the bacterial species set forth in Table 1 have thus far been associated with this syndrome, despite extensive

investigation. In fact, the only equine micropathology directly linked to the caterpillars themselves are the recently recognized intestinal granulomatous lesions associated with Eastern tent caterpillar setal fragments.^{8,9}

This hypothesis may also explain why no significant hormonal patterns or other clinical chemistry changes have yet been identified in the aborting mares. Early and late fetal loss are dependent on the direct and relatively nonspecific seeding of small amounts of bacterial contaminants into the fetal membranes, followed by bacterial proliferation and abortion.

Whereas MRLS is clearly associated with the hematogenous distribution of different bacterial species, it has not, to our knowledge, been possible to convincingly demonstrate a bacteremia associated with this condition. The septic penetrating setal emboli portion of the hypothesis, which suggests that the invading bacteria are carried in discrete quanta on or in very small numbers of setal fragments, may explain the lack of apparent evidence of bacteremia in natural and experimental MRLS. For example, a total of 10 setal fragments per day distributing in the blood of any single horse should yield about 1.5 late fetal loss “hits” per day, and these late fetal loss “hits” will be distributed through a relatively large volume (about 63.5 kg) of fetoplacental tissue.

This hypothesis for MRLS is grounded in well-established physics and mechanics for the movement of barbed fragments through motile soft tissues and the likelihood of bacterial contamination of such barbed fragments. The bacterial contaminants then distribute throughout the horse. The authors propose that this hypothesis accounts for all of the unique mathematical, toxicologic, epidemiologic, clinical, pathologic, and bacteriologic characteristics of the five MRLS syndromes associated with exposure to Eastern tent caterpillars as set forth here and in previous communications.

If this setal hypothesis is correct, then similar exposure to mechanical and bacteriologically equivalent setae from other cater-

pillar species or from any other mechanically equivalent structure may also have the potential to produce syndromes akin to MRLS. It is acknowledged that one study with Forest tent caterpillars failed to reproduce MRLS; however, a frozen gypsy moth hairy caterpillar (*Lymantria dispar*) in one study was associated with a single abortion event in one of four exposed mares.¹⁶

EXPERIMENTAL TESTS

Persons skilled in the art of experimental design will readily recognize appropriate tests of this hypothesis. As a first step, it would be instructive to administer high doses of Eastern tent caterpillars to nonpregnant horses, followed by necropsy of the animals. If the septic penetrating setal emboli portion of this hypothesis is correct, then micropathologic evidence of setal penetration in the intestinal tract and the intestinal portal circulation may be identified, as has recently been identified in pigs and rats, and apparently in a single horse.¹⁰ Additionally, since the role of the setae is to carry bacteria, increased bacterial counts may be identified in tissues exposed to septic setal fragments. However, a concern is the very small numbers and physical footprint of setal fragments, which could make it difficult to identify histopathologic or microbiologic changes in tissues distant from the intestinal tract. As MRLS itself has shown, the fetoplacental unit of the mare—especially the late pregnant mare—is an exquisitely and acutely sensitive detector of the hematogenous dispersion of septic material.

The septic penetrating setal emboli portion of the hypothesis is probably easily tested. Significant numbers of setal fragments approximately the same size or smaller than those observed in pig intestinal tracts, or similar in size to those presented in Figure 3, exposed to selected, specific MRLS-related bacteria that are suitably characterized or marked (genetically or otherwise) should rapidly induce MRLS following IV injection, and the bacteriologic evaluation of the fetal membranes should reflect the specific

bacterial additions to the setal fragments. Suitable controls would include IV injection of similar numbers of bacteria without setae. Injection of sterile setae should be much less effective than bacteria-coated setae, although what the simple mechanical effect of setae themselves might be on a pregnancy is unclear. Similarly, amniocentesis with introduction of very small numbers of these same bacteria should also rapidly induce abortions, and it would be instructive to see whether not such introductions produced classical MRLS micropathology, including the characteristic funisitis.

REFERENCES

1. Cadera W, Pachtman MA, Fountain JA, Ellis FD, Wilson FM: Ocular lesions caused by caterpillar hairs (ophthalmia nodosa). *Can J Ophthalmol* 1984; 19:40–44.
2. Fraser SG, Dowd TC, Bosanquet RC: Intraocular caterpillar hairs (setae): Clinical course and management. *Eye* 1994; 8:596–598.
3. Steele C, Lucas DR, Ridgway AEA: Endophthalmitis due to caterpillar setae: Surgical removal and electron microscopic appearances of the setae. *Brit J Ophthalmol* 2003; 68:284–288.
4. McDowell K, Webb B: Deductive Investigation of the Causes of Mare Reproductive Loss Syndrome: Experiment 4. Available at: <http://www.uky.edu/Agriculture/VetScience/mrls/Deductive%20Investigation060603.html>. Accessed April 26, 2004.
5. Cox N: Researchers Get Closer to Solving Caterpillar Mystery. Available at: http://www.uky.edu/Agriculture/VetScience/mrls/062603Closesto_solving.html. Accessed April 26, 2004.
6. Tobin T: Mare Reproductive Loss Syndrome and Associated Syndromes: Toxicological Hypothesis: Summary. In: Powell DG, Troppmann A, Tobin T, eds. *Workshop on Mare Reproductive Loss Syndrome*. Lexington, KY, University of Kentucky College of Agriculture, 2003:75–76.
7. Tobin T: Septic Penetrating Setae/Septic Emboli/Septic Penetrating Setal Emboli (SPS/SE/septic penetrating setal emboli): A hypothesis to explain the pathogenesis of the Mare Reproductive Loss Syndrome. *Copyright #TXU1111484:2003 registered at Library of Congress, June 17, 2003*.
8. McDowell K, Williams NM, Donahue JM, et al: Eastern Tent Caterpillars Cause Abortions in Pregnant Pigs. Available at: http://www.uky.edu/Agriculture/VetScience/mrls/090503Eastern_tent_caterpillarsabortpigs.html. Accessed April 24, 2004.
9. Fitzgerald TD: Setae and MRLS, Article #4609. September 2003. Available at: <http://www.TheHorse.com>. Accessed April 24, 2004.
10. McDowell K, Williams NM, Donahue JM, Webb B, Newman K, Lynn B: Eastern Tent Caterpillar Setae in Digestive Tract of Mare. Available at: http://www.uky.edu/Agriculture/VetScience/mrls/091903Eastern_tent_caterpillars-setae.html. Accessed April 24, 2004.
11. Sebastian M, Gantz M, Tobin T, et al: The mare reproductive loss syndrome and the Eastern tent caterpillar: A toxicokinetic/statistical analysis with clinical, epidemiological, and mechanistic implications. *Vet Ther* 2003; 4:324–339.
12. Hong CB, Donahue JM, Giles RC, et al: Equine abortion and stillbirth in central Kentucky during 1985 and 1989 foaling seasons. *J Vet Diagn Invest* 1993; 5:560–566.
13. Rocha G, Baines MG, Deschenes J: The immunology of the eye and its systemic interactions. *Crit Rev Immunol* 1992; 12:81–100.
14. Sebastian M, Williams D, Harrison LR, et al: Experimentally induced mare reproductive loss syndrome late fetal losses with Eastern tent caterpillars. In: Powell DG, Troppmann A, Tobin T, eds. *Workshop on Mare Reproductive Loss Syndrome*. Lexington, KY, University of Kentucky Department of Agriculture 2003:80–81.
15. Herbert KS: Outside of caterpillar might be linked to MRLS. Article #4042. Available at: <http://www.TheHorse.com>. Accessed April 24, 2004.
16. Webb BA, Barney WE, Dahlman DL, et al: Eastern tent caterpillars (*Malacosoma americanum*) cause mare reproductive loss syndrome. *J Insect Physiol* 2004; 50:185–193.
17. Sebastian M, Harkins JD, Jackson C, et al: A laboratory animal model of mare reproductive loss syndrome: Preliminary evaluation of a mouse model. In: Powell DG, Troppmann A, Tobin T, eds. *Workshop on Mare Reproductive Loss Syndrome*. Lexington, KY, University of Kentucky College of Agriculture 2002:51–53.
18. Knapp G: Ophthalmia nodosa. *Am J Ophthalmol* 1897; 14:247–252.
19. Horng CT, Chou PI, Liang JB: Caterpillar setae in the deep cornea and anterior chamber. *Am J Ophthalmol* 2000; 129:384–385.
20. Vissenberg I, Raus P, Van Tittleboom T, Dockx P, Tassignon MJ: Caterpillar-induced kerato-conjunctivitis. *Bull Soc Belge Ophthalmol* 1993; 249:107–111.

21. Pitetti RD, Kuspis D, Krenzelok EP: Caterpillars: An unusual source of ingestion. *Pediatr Emerg Care* 1999; 15:33–36.
22. de Jong MCJM, Bleumink E, Nater JP: Investigative studies of the dermatitis caused by the larva of the brown-tail moth (*Euproctis chrysorrhoea* Linn.). *Arch Derm Res* 1975; 253:287–300.
23. Hesler LS, Logan TM, Benenson MW, Moser C: Acute dermatitis from oak processionary caterpillars in a US military community in Germany. *Mil Med* 1999; 164:767–770.
24. Ziprowski I, Hofshi E, Tahori AS: Caterpillar dermatitis. *Isr Med J* 1985; 18:26–31.
25. Balit CR, Ptolemy HC, Geary MJ, Russell RC, Isbister GK: Outbreak of caterpillar dermatitis caused by airborne hairs of the mistletoe brown-tail moth (*Euproctis edwardsi*). *Med J Australia* 2001; 175:641–643.
26. Chang PCT, Soonz HK, Barnett JM: Corneal penetration by tarantula hairs. *Brit J Ophthalmol* 1991; 75:253–254.
27. Williams MM, Wilcock BP: Traumatic exogenous uveitis. *Vet Comp Ortho Trauma* 1988; 1:35–37.
28. Weiss BF, Wolfenden HD: Survivor of a stingray injury to the heart. *Med J Australia* 2001; 175:33–34.
29. Obendorf DL and Presidente PJ: Foreign body perforation of the esophagus initiating traumatic pericarditis in an Australian fur seal. *J Wildlife Dis* 1978; 14:451–454.
30. Cormier SM, Hessinger DA: Cellular basis for tentacle adherence in the Portuguese man-of-war (*Physalia physalis*). *Tissue Cell* 1980; 12:713–721.
31. Blomkalns AL, Otten EJ: Catfish spine envenomation: A case report and literature review. *Wild Environ Med* 2003; 10:242–246.
32. Rollins JB, Crabo MG, Clement TH, Park RD: Ultrasonographic identification of cactus spines in the distal extremity of three horses. *Equine Pract* 1995; 17:31–33.
33. Adams CD, Timms FJ, Hanlon M: Phoenix date palm injuries: A review of injuries from the Phoenix date palm treated at the Starship Children's Hospital. *Australian NZ J Surg* 2000; 70:355–357.
34. Schneider DJ, duPlessis JL: Enteritis in sheep due to the ingestion of *Inula graveolens* Desf (Cape Khakiweed). *J S Afr Vet Assoc* 1980; 51:159–161.
35. Brennan KE, Ihrke PJ: Grass awn migration in dogs and cats: a retrospective study of 182 cases. *JAVMA* 1983; 182:1201–1204.
36. Gillespie JR, Tyler WS: Chronic alveolar emphysema in the horse. *Adv Vet Sci* 1969; 13:59–99.
37. Littlejohn A, Bowles F, Maluleka W: Studies on the physiopathology of chronic obstructive pulmonary disease in the horse. VII. Percentage of venous admixture. *Onderstepoort J Vet Res* 1982; 49:211–214.
38. Blood DC, Radostits OM, Henderson JA: *Veterinary Medicine*. London; Bailliere Tindall:1983.
39. Hogan DJ: Subungual trichogranuloma in a hairdresser. *Cutis* 1988; 42:105–106.
40. Patel MR, Bassini L, Nashad R, Anselmo MT: Barber's interdigital pilonidal sinus of the hand: A foreign body hair granuloma. *J Hand Surg* 1990; 15A:652–655.
41. Arocha-Pinango CL, Marval E, Guerrero B: *Lonomia* genus caterpillar toxins: biochemical aspects. *Biochimie* 2000; 82:937–942.
42. Weld JM, Kamerling SG, Combie J, Nugent TE, Woods WE: The effects of naloxone on endotoxin and hemorrhagic shock in horses. *Res Commun Chem Pathol Pharmacol* 1984; 44:227–238.
43. Harkins JD, Carney JM, Meier M, Leak SC, Tobin T: Effect of α -phenyl-tert-butyl nitron on endotoxin toxemia in horses. *Vet Hum Toxicol* 1997; 39:268–271.
44. de Roodt AR, Salomon OD, Orduna TA: Accidents due to lepidoptera with special reference to *Lonomia* sp. *Medicina* (Buenos Aires) 2000; 60:964–972.
45. Dirikolu L, Hughes C, Harkins D, et al: The toxicokinetics of cyanide and mandelonitrile in the horse and their relevance to the mare reproductive loss syndrome. *Toxicol Mechanisms Methods* 2002; 13:199–211.
46. Hughes C, Lehner AF, Crutchfield J, et al: Analytical detection and "normal" population data of cyanide and thiocyanate in equine blood and serum. *Toxic Mechanisms Methods*; In Press:2004.
47. Hughes C, Lehner AF, Dirikolu L, et al: A simple and highly sensitive spectrophotometric method for determination of cyanide in equine blood. *Toxic Mechanisms Methods* 2003; 13:129–138.
48. J Donahue, S Sells, R Giles, et al: Bacteria associated with mare reproductive loss syndrome: Late fetal losses. Session #2: Laboratory Correlates of MRLS. In: Powell D, Troppmann A, Tobin T, eds. *Workshop on Mare Reproductive Loss Syndrome*. Lexington, KY, University of Kentucky College of Agriculture 2002:27–29.